



Patient

NHS No

D.O.B.

Patient Ref

Reason

Claudication

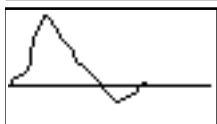
Outcome

Occlusion, Calcified

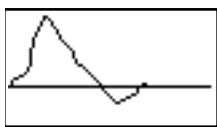
Right

180

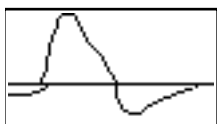1.00



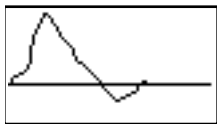
Good



Good



see notes



Good

175

0.97

Brachial

Common Femoral

High Thigh

Low Thigh

Popliteal

High Calf

Peroneal

Anterior Tibial

Posterior Tibial

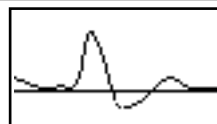
Dorsalis Pedis

Toe Pressure

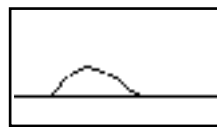
Post Exercise

Left

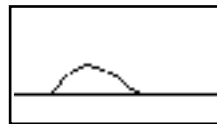
Good



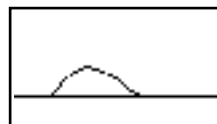
Weak



Weak



Weak



Weak/Absent



Notes

BILATERAL LOWER LIMB ARTERIAL PRESSURES & WAVEFORMS ASSESSMENT; full assessment carried out on the left due to findings.

RIGHT PRESSURES & WAVEFORMS ASSESSMENT (PERIPHERAL ASSESSMENT)

Good biphasic waveforms detected in the right common femoral, popliteal and posterior tibial arteries. Biphasic waveforms also detected in the anterior tibial artery, however poor colour-filling obtained ?full vessel patency.

Assessed by

Lukasz Koprowski

Checked by

Patient

NHS No

D.O.B.

Patient Ref

LEFT (full assessment)

Common iliac artery appears patent, good biphasic waveforms, PSV 99cm/s.

External iliac artery appears patent, good triphasic waveforms, PSV 178cm/s.

Common femoral artery appears mildly diseased, good triphasic waveforms, PSV 184cm/s.

Profunda femoral artery (origin) appears patent, good triphasic waveforms, PSV 73cm/s.

Superficial femoral artery (SFA) origin appears patent, good triphasic waveforms, PSV 95cm/s. Proximal thigh contains diffuse, mild-moderate disease, triphasic waveforms, 136cm/s. An ~4cm occlusion noted at mid thigh (~54- ~50cm prox to MM), with weak monophasic waveforms, PSV 35cm/s in the distal thigh.

Popliteal artery appears patent, weak monophasic waveforms, PSV 28cm/s. TPT appears patent; origins of 2 vessel run-off noted.

Posterior tibial artery contains intermittent, weak monophasic flow, PSV 20cm/s ?full vessel patency.

Peroneal artery appears patent, weak monophasic waveforms, PSV 18cm/s at the ankle

Anterior tibial artery appears patent, weak monophasic waveforms, PSV 16cm/s.

Resting ABPI is within normal limits on the right, but unable to obtain resting ABPI on the left due to the weakness of crural signals.

